Atrophies of Connective Tissue 99

Catherine Maari and Julie Powell

Chapter Contents

Mid-dermal Elastolysis 1741
Anetoderma. 1742
Striae 1745
Atrophoderma of Pasini and Pierini 1746
Follicular Atrophoderma 1748
Atrophia Maculosa Varioliformis Cutis 1749
Piezogenic Pedal Papules (Piezogenic Papules) 1749
Other Atrophies of the Connective Tissue 1750

Atrophies of the skin that are due to a diminution or loss of collagen and/or elastic fibers are discussed in this chapter. The areas of involvement can be quite large, as in mid-dermal elastolysis, or punctate, as in follicular atrophoderma. In most disorders, the underlying pathogenesis remains to be discovered.

MID-DERMAL ELASTOLYSIS

Key features

- Uncommon disorder with areas of fine wrinkling
- Usually affects White middle-aged women
- Selective loss of elastic tissue in the mid dermis

Introduction

Mid-dermal elastolysis (MDE) is a rare, acquired disorder of elastic tissue. Clinically, it is usually characterized by diffuse fine wrinkling, most often located on the trunk, shoulders, neck, and arms. Histologically, a clear band of elastolysis with loss of elastic fibers is present in the mid dermis.

History

In 1977, Shelley and Wood reported the first case of "wrinkles due to idiopathic loss of mid-dermal elastic tissue". Their patient, a 42-year-old woman, had circumscribed areas of fine wrinkles that gave her an inappropriately aged appearance[1].

Epidemiology

To date, around 100 cases have been reported in the literature. The vast majority of patients are White women between the ages of 30 and 50 years[2,3].

Pathogenesis

The cause of the acquired elastic tissue degeneration in MDE has yet to be determined. Exposure to UV light, including natural sunlight, UVA (tanning salon), and narrowband UVB phototherapy[4,5], was thought to be a contributing factor in MDE, but this remains unclear[3]. Other hypotheses include defects in the synthesis of elastic fibers, autoimmunity against elastic fibers, and damage to elastic fibers via the release of elastase by inflammatory cells or fibroblasts. Of note, MDE has been observed in the setting of immune reconstitution inflammatory syndrome (IRIS). An imbalance between matrix metalloproteinases (MMPs) and tissue inhibitors of metalloproteinases (TIMPs) may also be playing a role, in addition to $CD34^+$ dendritic fibroblasts[6].

A decrease in lysyl oxidase-like 2 (LOXL2) expression, potentially affecting elastin renewal, has been observed in MDE[7]. There is also a decrease in dermal fibulin-4 and -5, pointing to altered re-assembly of elastic fibers in MDE, and not simply enhanced elastolysis[8]. In sum, the pathogenesis of MDE is likely multifactorial, with genetic predisposition, chronic inflammation, UV irradiation, and/or (auto)immune processes as contributing factors[3].

Clinical Features

Patients can have well-circumscribed to large diffuse areas of fine wrinkling (Fig. 99.1), usually in a symmetric distribution (type I). The wrinkles themselves tend to follow cleavage lines. Discrete perifollicular papules are seen in some patients (type II), with the site of the central hair follicle being indented. Occasionally, erythematous patches, telangiectasias, and reticulated erythema may be present (type III)[3]. Although in the majority of patients there is no history of a prior inflammatory dermatosis, some patients report previous mild to moderate erythema and, rarely, elastolysis is preceded by urticarial lesions or granuloma annulare.

Sites of predilection are the trunk, lateral neck, and upper extremities. Once the patches of wrinkling have appeared, they usually remain stationary. They are asymptomatic and give the skin a prematurely aged appearance. The affected areas usually have normal pigmentation and no associated scaling, induration, or herniation. There is typically no family history of similar lesions and unless linked to an autoimmune disorder, no systemic involvement[2,3]. MDE can lead to significant cosmetic concern.

While diagnosis is usually confirmed via histologic examination of involved skin, non-invasive imaging techniques such as optical coherence microscopy or high-frequency ultrasound may also prove helpful[9].

Pathology

The epidermis is normal in appearance and, occasionally, a mild perivascular infiltrate is noted in the dermis. Elastic tissue stains, such as Verhoeff–van Gieson or Weigert's stain, reveal a selective loss of elastic fibers in the mid dermis (Fig. 99.2). There is preservation of normal elastic tissue in the superficial papillary dermis above, in the reticular dermis below, and along adjacent hair follicles. The preservation of elastic tissue around the hair follicles explains the perifollicular papules observed in some patients.

By electron microscopy, phagocytosis of normal as well as degenerated elastic fiber tissue by macrophages has been described[3]. Elastophagocytosis by macrophages can also be observed by routine histology.

Differential Diagnosis

MDE must be differentiated from other disorders of elastic tissue such as anetoderma, pseudoxanthoma elasticum (PXE), PXE-like papillary dermal elastolysis, elastoderma, and cutis laxa, especially the acquired form (Table 99.1).

Clinically, anetoderma is characterized by soft macules and papules that herniate upon palpation, as opposed to diffuse wrinkling. Histologically, elastolysis can occur in the papillary and/or mid-reticular dermis in anetoderma (see below). Patients with heritable forms of generalized cutis laxa have loose, redundant skin, hanging in folds, and histologic examination shows reduced and fragmented elastic fibers, usually within the entire dermis. Acquired cutis laxa, both generalized and acral, can be a manifestation of an underlying paraproteinemia, with binding of immunoglobulins to elastic fibers (see Table 97.8).

Less often, MDE is confused with solar elastosis or the perifollicular elastolysis that is usually seen on the trunk in association with acne

Downloaded for Anonymous User (n/a) at Egyptian Knowledge Bank from ClinicalKey.com by Elsevier on March 10, 2024. For personal use only. No other uses without permission. Copyright ©2024. Elsevier Inc. All rights reserved.

Fig. 99.1 Mid-dermal elastolysis. A, B Type I – large diffuse patch as well as reticulated areas of fine wrinkling on the upper trunk and proximal arm. The junction of involved and uninvolved skin is marked with an arrow. **C** Types I and II – both circumscribed areas of wrinkling and follicular papules are present. **D** Type II – multiple skin-colored follicular papules. **E** Type III – primarily reticulated erythema. *A, Courtesy Judit Stenn, MD; B, Courtesy Carlo F. Tomasini, MD; C–E, Courtesy Lorenzo Cerroni, MD.*

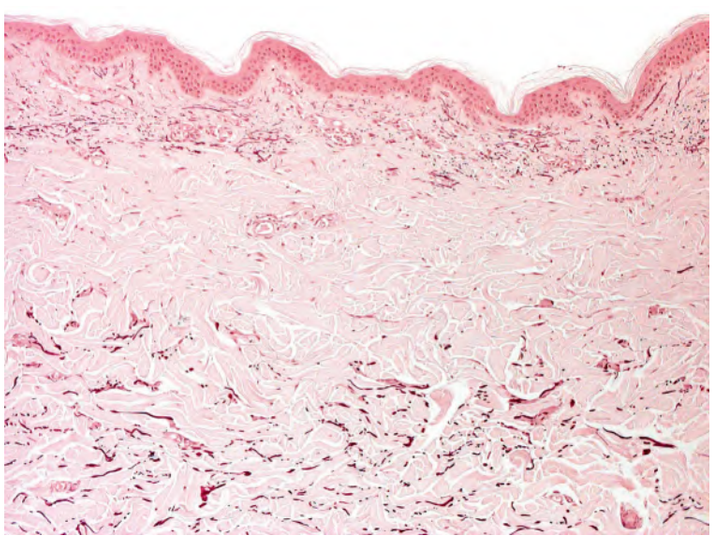

Fig. 99.2 Mid-dermal elastolysis – histopathologic features. A near absence of elastic fibers in a band-like distribution in the mid reticular dermis. Identification of these changes requires an elastic tissue stain (e.g. orcein). *Courtesy Lorenzo Cerroni, MD.*

vulgaris. Solar elastosis differs clinically by its onset in an older age group, restriction to only sun-exposed areas, yellow color, and coarser wrinkling and differs histologically by hyperplasia of abnormal elastic fibers and basophilic degeneration of the collagen in the papillary dermis. Perifollicular elastolysis leads to a selective and almost complete loss of the elastic fibers that surround hair follicles, compared with preservation of elastic fibers around follicles in MDE.

Treatment

Currently, there is no effective treatment for MDE. Sunscreens, colchicine, chloroquine, vitamin E, and topical agents (retinoic acid, corticosteroids) have been tried without success[2]. Topical soybean extract and eicosapentanoic acid are potential future therapies and oral mycophenolate mofetil may be beneficial[2,10].

ANETODERMA

Synonyms: ▪ Macular atrophy ▪ Anetoderma maculosa ▪ Anetoderma maculosa cutis ▪ Atrophia maculosa cutis

Key features

- Circumscribed 1–2 cm areas of flaccid skin, which may be elevated, macular, or depressed
- *Primary* anetoderma has classically been divided into inflammatory and non-inflammatory
- *Secondary* anetoderma is associated with infectious and inflammatory cutaneous disorders as well as tumors and autoimmune disorders (e.g. antiphospholipid antibody syndrome)
- Histologically, focal absence of dermal elastic tissue is seen

Downloaded for Anonymous User (n/a) at Egyptian Knowledge Bank from ClinicalKey.com by Elsevier on March 10, 2024. For personal use only. No other uses without permission. Copyright ©2024. Elsevier Inc. All rights reserved.

DISORDERS OF ELASTIC TISSUE			
Condition	**Clinical findings**	**Site of predilection**	**Pathology**
Anetoderma	• Multiple circumscribed areas of flaccid skin • Lesions are often elevated (protruding), but can be macular or depressed	Usually on trunk	Focal or complete loss of elastic tissue in the papillary and/or reticular dermis
Cutis laxa (see Ch. 97)	• Loose, sagging skin folds resulting in prematurely aged appearance • Hereditary or acquired • Internal organ involvement, e.g. pulmonary, in hereditary form and generalized acquired form	Eyelids, cheeks, neck, shoulder girdle and abdomen; distal digits in acquired acral form	Diminished and fragmented elastic fibers usually throughout the dermis
Mid-dermal elastolysis	• Diffuse areas of fine wrinkling (type I), perifollicular papules (type II), and/or reticulated erythema (type III) in middle-aged women	Trunk, arms, and lateral neck	Selective loss of elastic fibers within the mid dermis in a band-like pattern
Pseudoxanthoma elasticum (PXE; see Ch. 97)	• Yellowish coalescing skin papules, "cobblestoning", and redundant folds in flexural sites • Associated ocular and cardiovascular involvement	Lateral neck, axillae, and groin; scars	Clumped and calcified elastic fibers in the mid dermis
PXE-like papillary dermal elastolysis	• Multiple, 2–3 mm, yellow or skin-colored papules that can coalesce into cobblestoned plaques	Neck, flexor forearms, axillae, lower abdomen, inframammary folds	Decreased elastic tissue in the papillary dermis (band-like pattern); clumping and fragmentation of elastic fibers; no calcification of elastic fibers

Table 99.1 Disorders of elastic tissue. For additional entities, see Tables 95.5, 97.4 and 97.7.

Introduction

The term "anetoderma" is derived from *anetos*, the Greek word for slack, and *derma* for skin. Anetoderma is an elastolytic disorder characterized by localized areas of flaccid skin, which may be depressed, macular or papular; the latter can reflect herniation of the subcutaneous tissue. Anetoderma may be idiopathic or associated with an inflammatory disorder of the skin.

History

The first case of primary inflammatory anetoderma was reported by Jadassohn in 1892[11]. A year previously, Schweninger and Buzzi described a 29-year-old woman with multiple, non-inflammatory, sac-like tumors on the trunk and upper extremities[12].

Epidemiology

Several hundred cases of anetoderma have been reported in the world literature. Primary anetoderma favors young adults between 15 and 25 years of age and occurs more frequently in women than men. The epidemiology of secondary anetoderma reflects that of the underlying etiologies (see Table 99.3).

Pathogenesis

The pathogenesis of anetoderma is not known. These lesions could be considered unusual scars, since scars also have decreased elastic tissue. The loss of dermal elastin may reflect an impaired turnover of elastin, caused by either increased destruction or decreased synthesis of elastic fibers. There are a number of proposed explanations for the focal elastin destruction, e.g. the release of elastase from inflammatory cells, the release of cytokines such as interleukin-6, an increased production of progelatinases A and B[13], and the phagocytosis of elastic fibers by macrophages. More recently, a decrease in fibulin protein expression was observed, suggesting defective elastic fiber reassembly[6]. Immunologic mechanisms may also play a role, providing an explanation for associated findings such as antiphospholipid antibodies (see below). Based upon a few isolated patients, a link may exist between anetoderma and mutations in genes that encode enzymes in the citric acid cycle[14].

In *primary* anetoderma, there is no underlying associated disorder and lesions arise within clinically normal skin. It has classically been subdivided into two major forms: those with preceding inflammatory lesions (the Jadassohn–Pellizzari type) and those without preceding inflammatory lesions (the Schweninger–Buzzi type) (Table 99.2). This clinical classification is primarily of historical interest, since the two types of lesions can coexist in the same patient and their histopathology is often the same; the presence or absence of clinical inflammation at the onset of the disease is not related to prognosis[15].

CLASSIFICATION OF ANETODERMA	
Primary anetoderma	• Jadassohn–Pellizzari type: preceding inflammatory lesionsSchweninger–Buzzi type: no preceding inflammatory lesions
Secondary anetoderma	• Associated with a primary dermatosis or cutaneous tumorAssociated with a systemic disease (autoimmune, antiphospholipid syndrome, infectious) or drug
Familial anetoderma	• Both autosomal dominant and autosomal recessive formsUsually develops in first decade of life
Anetoderma of prematurity	• Occurs in extremely premature infants • At sites of monitoring leads or adhesives

Table 99.2 Classification of anetoderma.

Secondary anetoderma can arise in the setting of a primary inflammatory dermatosis, skin infection or cutaneous tumor, as well as in patients with systemic disorders (e.g. autoimmune). Over the past decade, an association with antiphospholipid antibody syndrome has been highlighted. Although the vast majority of cases are sporadic, familial anetoderma has been described and is usually not associated with pre-existing lesions[16].

Clinical Features

The characteristic lesions are flaccid, circumscribed areas of slack skin that are a reflection of a marked reduction or absence of dermal elastic fibers; they can appear as depressions, wrinkling, or sac-like protrusions (Fig. 99.3). These atrophic lesions vary in number from a few to hundreds, and they typically measure 1–2 cm in diameter and are skin-colored to bluish–white in color. The skin surface can be normal in appearance or wrinkled, and a central depression may be seen. Coalescence of smaller lesions can give rise to larger herniations.

The examining finger sinks into a distinct pit with sharp borders as if into a hernia ring. The bulge reappears when the pressure from the finger is released. This clinical finding is referred to as the "buttonhole" sign and is similar to that observed in neurofibromas.

Predilection sites for these asymptomatic lesions are the chest, back, neck, and upper extremities. Primary anetoderma usually develops in young adults, and new lesions often continue to form for many years as the older lesions fail to resolve.

True secondary anetoderma implies that the characteristic atrophic lesion has appeared in the same site as a previous specific skin lesion, e.g. from varicella or leprosy. Some authors also consider lesions associated

Downloaded for Anonymous User (n/a) at Egyptian Knowledge Bank from ClinicalKey.com by Elsevier on March 10, 2024. For personal use only. No other uses without permission. Copyright ©2024. Elsevier Inc. All rights reserved.

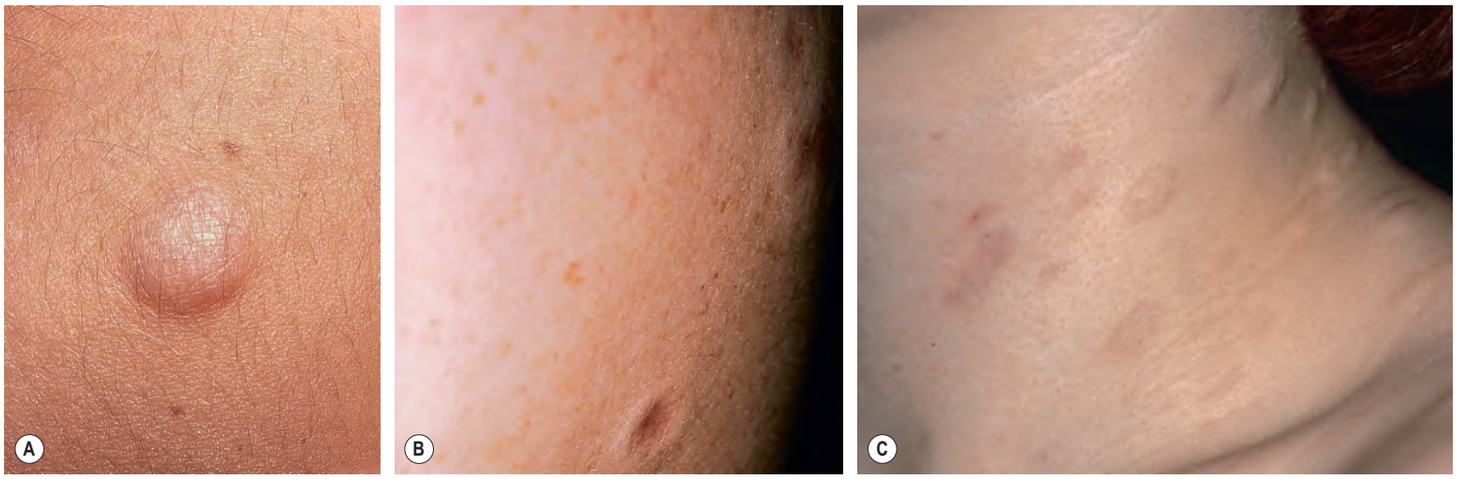

Fig. 99.3 Primary anetoderma. Lesions can range from soft, skin-colored papules that herniate upon palpation (**A**) to flaccid papules that have a central depression (**B**). The upper trunk and neck is a common location for primary anetoderma (**C**). *A, Courtesy Ronald P. Rapini, MD; C, Courtesy Thomas Schwarz, MD.*

with an underlying disease (e.g. HIV infection, antiphospholipid antibody syndrome, autoimmune thyroiditis) as secondary anetoderma; however, in this instance, the atrophic areas do not necessarily develop within areas of known inflammation. Evaluation for the presence of antiphospholipid antibodies should be performed before patients with idiopathic anetoderma are labeled as having primary anetoderma[17]. The range of heterogeneous conditions associated with secondary anetoderma are outlined in Table 99.3. With the exception of distribution (and perhaps size), the clinical features are the same as those of primary anetoderma.

Anetoderma has increasingly been reported in premature infants. In most neonates, it appears to be related to the use of cutaneous monitoring leads or adhesives[18], as well as extreme prematurity[18].

In patients with anetoderma, a variety of systemic abnormalities have been reported, including ocular, endocrinologic, skeletal, cardiac, pulmonary, and gastrointestinal disease. Because there has been no consistency with regard to these associated abnormalities, they are probably coincidental, although the possibility exists that they may reflect a more generalized elastolytic disorder that has yet to be defined.

Pathology

In routinely stained sections, the collagen within the dermis of affected skin appears normal. Perivascular lymphocytes, primarily T helper cells, are often present but do not correlate with clinical findings of inflammation.

The predominant abnormality, revealed by elastic tissue stains, is a focal, more or less complete loss of elastic tissue in the papillary and/or reticular dermis. There are usually some residual abnormal, irregular, and fragmented elastic fibers (Fig. 99.4)[19]. In addition to plasma cells and histiocytes with phagocyted elastic fibers, occasional granuloma formation can be seen.

Direct immunofluorescence sometimes shows linear or granular deposits of immunoglobulins and complement along the dermal–epidermal junction or around the dermal blood vessels in affected skin[20]. However, these findings are not helpful diagnostically.

By electron microscopy, the elastic fibers are fragmented and irregular in shape and occasionally they are engulfed by macrophages.

Differential diagnosis

Anetoderma must be differentiated from other disorders of elastic tissue such as MDE (see Table 99.1) as well as atrophodermas (see below). However, the major differential diagnosis consists of post-traumatic scars and papular elastorrhexis[21]. The latter is an acquired disorder characterized by firm, white, non-follicular papules that measure 2–5 mm in diameter and are evenly scattered on the trunk. The lesions usually appear during adolescence or early adulthood. Histology demonstrates focal degeneration of elastic fibers and normal collagen. There are no associated extracutaneous abnormalities. This disorder is believed by some authors to be a variant of connective tissue nevi or an abortive form of the Buschke–Ollendorff syndrome, while others think that these lesions represent papular acne scars. In contrast to anetoderma, lesions of papular elastorrhexis are firm and non-compressible.

Less often, anetoderma is confused with perifollicular elastolysis (see above), nevus lipomatosus, or focal dermal hypoplasia (Goltz

SECONDARY ANETODERMA – ASSOCIATED CONDITIONS	
Infectious	• Varicella • Folliculitis* • Lepromatous leprosy • Syphilis (cutaneous) • Molluscum contagiosum • Tuberculosis (cutaneous) • HIV infection • Acrodermatitis chronica atrophicans • Post-hepatitis B immunization
Drugs	• Penicillamine • Cabiralizumab (CSF1 receptor antagonist) plus nivolumab**
Inflammatory	• Acne vulgaris • Lichen planus • Neutrophilic dermatoses (Sweet syndrome, pyoderma gangrenosum) • Granuloma annulare • Cutaneous sarcoidosis • Juvenile xanthogranuloma • Cutaneous lymphoid hyperplasia (lymphocytoma cutis) • Insect bites • Prurigo nodularis
Autoimmune	• Cutaneous (e.g. discoid, panniculitis) and systemic lupus erythematosus • Antiphospholipid syndrome • Primary Sjögren syndrome • Addison disease • Graves disease
Tumors and depositions	• Involuted infantile hemangioma • Pilomatricoma • Melanocytic nevus • Schwannoma • Dermatofibroma • Dermatofibrosarcoma protuberans • Primary cutaneous marginal zone B cell lymphoproliferative disorder (formerly primary cutaneous plasmacytoma or immunocytoma) • Mycosis fungoides • Mastocytosis • Nodular amyloidosis • Xanthoma

*May overlap with perifollicular elastolysis.
**Preceding granulomatous inflammation with elastolysis.

Table 99.3 Secondary anetoderma – associated conditions.

Downloaded for Anonymous User (n/a) at Egyptian Knowledge Bank from ClinicalKey.com by Elsevier on March 10, 2024. For personal use only. No other uses without permission. Copyright ©2024. Elsevier Inc. All rights reserved.

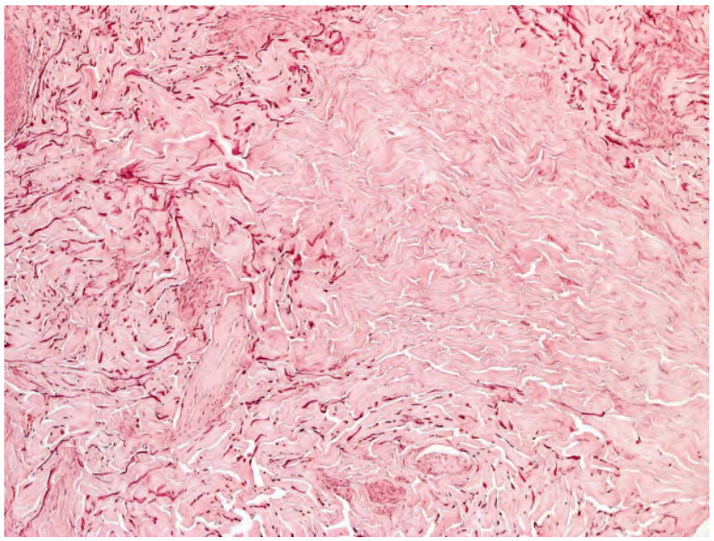

Fig. 99.4 Anetoderma – histopathologic features. A decrease of elastic fibers in both the papillary and reticular dermis (Weigert's stain). *Courtesy Lorenzo Cerroni, MD.*

syndrome). Nevus lipomatosus superficialis of Hoffman and Zurhelle presents as a clustered group of soft, skin-colored to yellow nodules, usually located on the lower trunk and present since birth (see Ch. 117). Histology shows ectopic mature lipocytes located within the dermis. The lesions of Goltz syndrome (including telangiectasias, vermiculate dermal atrophy, hypopigmentation, hyperpigmentation, and fatty herniations/hamartomas) are in a linear array along the lines of Blaschko (see Ch. 62). Histologically, a decrease in dermal content is seen as well as extension or deposition of subcutaneous fat into the dermis.

Treatment

Various therapeutic modalities have been tried, but have not resulted in improvement of existing atrophic lesions; these include intralesional triamcinolone and systemic administration of aspirin, dapsone, phenytoin, penicillin G, vitamin E, and inositol niacinate. Some authors have reported improvement with hydroxychloroquine. Surgical excision of limited lesions may be helpful, with informed consent from the patient regarding the risk of scar formation. The utility of soft tissue fillers is inconclusive. Based upon case reports, fractionated ablative and non-ablative lasers may be beneficial[22,23].

STRIAE

Synonyms: ▪ Striae distensae ▪ Striae atrophicans ▪ "Stretch marks" ▪ Striae gravidarum

Introduction

Striae are a very common condition in most age groups. They are linear atrophic depressions of the skin that form in areas of dermal damage produced by stretching of the skin. They are associated with various physiologic states, including puberty, pregnancy, rapid growth, weight gain or loss, obesity[24], and disorders that lead to hypercortisolism. Striae also develop at sites of potent topical corticosteroid application, in particular, occluded intertriginous zones.

History

Striae were first described by Roederer in 1773, and the first histologic descriptions were made by Troisier and Menetrier in 1889.

Epidemiology

Striae are very common and usually develop between the ages of 5 and 50 years. They are seen more commonly in White individuals and occur about twice as frequently in women as in men. They commonly develop during puberty, with a prevalence ranging from 5% to 85%[25], or during pregnancy, with an incidence of up to 90%[26].

Pathogenesis

Factors leading to the development of striae have not been fully elucidated. They are a reflection of "breaks" in the connective tissue that lead to dermal atrophy. A number of factors, including hormones (particularly corticosteroids), mechanical stress and genetic predisposition, appear to play a role. Bevacizumab, an anti-VEGF antibody well known for its negative effect on wound healing, has also been associated with severe ulcerations of corticosteroid-induced striae[27].

Clinical Features

Striae are usually multiple, symmetric, well-defined, linear atrophic lesions that often follow the lines of cleavage. They are usually more of a cosmetic concern, but rarely can ulcerate. Initially, striae appear as red-to-violaceous elevated lines that can be mildly pruritic and are called striae rubrae (Fig. 99.5). Over time, the color gradually fades, and the lesions become atrophic, exhibiting a fine wrinkled appearance. These striae albae are usually permanent, but they may fade somewhat over time[25]. The striae can measure several centimeters in length and a few millimeters to a few centimeters in width.

During puberty, striae appear in areas where there is a rapid increase in size. In girls, the most common sites are the thighs, hips, buttocks and breasts, whereas in boys, they are seen on the shoulders, thighs, buttocks, and lumbosacral region[25] (Fig. 99.6). Other less common sites include the abdomen, upper arms, neck, and axillae.

Striae distensae are a common finding on the abdomen, and less so on the breasts and thighs, of pregnant women, especially during the last trimester. They are more common in younger primigravidas than in older pregnant women, in those who gained more weight during pregnancy, and/or those who had babies with a higher birth weight[26]. The development of striae gravidarum has been associated with an increased risk of laceration during vaginal delivery as well as subsequent pelvic relaxation and clinical prolapse[28,29].

The striae associated with systemic corticosteroid therapy and Cushing syndrome can be larger and more widely distributed (see Ch. 53). Flexural and intertriginous areas are particularly at risk for developing striae from the use of potent topical corticosteroids.

Atrophic striae may become elevated and "worm-like" in the setting of severe edema, including lymphedema. In polymorphic eruption of pregnancy, initial lesions often arise within striae gravidarum.

Pathology

Histologic findings are similar to those of scars and depend upon the stage of evolution of the striae at the time the biopsy is performed. The epidermis can be normal during the early stages, but eventually becomes atrophic with blunted rete ridges. The dermal thickness is decreased, as is the collagen in the upper dermis. The collagen bundles lie parallel to the epidermis. Alterations in elastic fibers are variable, but they can be fragmented, and specific elastin staining can demonstrate a marked reduction compared with adjacent normal dermis[30]. There is an absence of both hair follicles and other adnexal structures.

Differential Diagnosis

The diagnosis of striae distensae is usually straightforward, but the differential diagnosis does include linear focal elastosis (elastotic striae), an entity first described by Burket et al.[31] in 1989. Linear focal elastosis is characterized by rows of yellow, palpable, striae-like bands on the lower back. Unlike striae, the lesions are raised and yellow rather than depressed and white. Elderly men are most commonly affected. Histologically, there is a focal increase in the number of elongated or fragmented elastic fibers as well as a thickened dermis. It is postulated that linear focal elastosis may represent an excessive regenerative process of elastic fibers and could be viewed as a keloidal repair of striae distensae[32].

Downloaded for Anonymous User (n/a) at Egyptian Knowledge Bank from ClinicalKey.com by Elsevier on March 10, 2024. For personal use only. No other uses without permission. Copyright ©2024. Elsevier Inc. All rights reserved.

Fig. 99.5 Striae. A Linear erythematous lesions on the abdomen (striae rubrae). **B** Atrophic linear lesions of striae albae in a teenager. **C** Large axillary striae in a patient receiving chronic, high-dose systemic corticosteroids. *B, Courtesy Kalman Watsky, MD.*

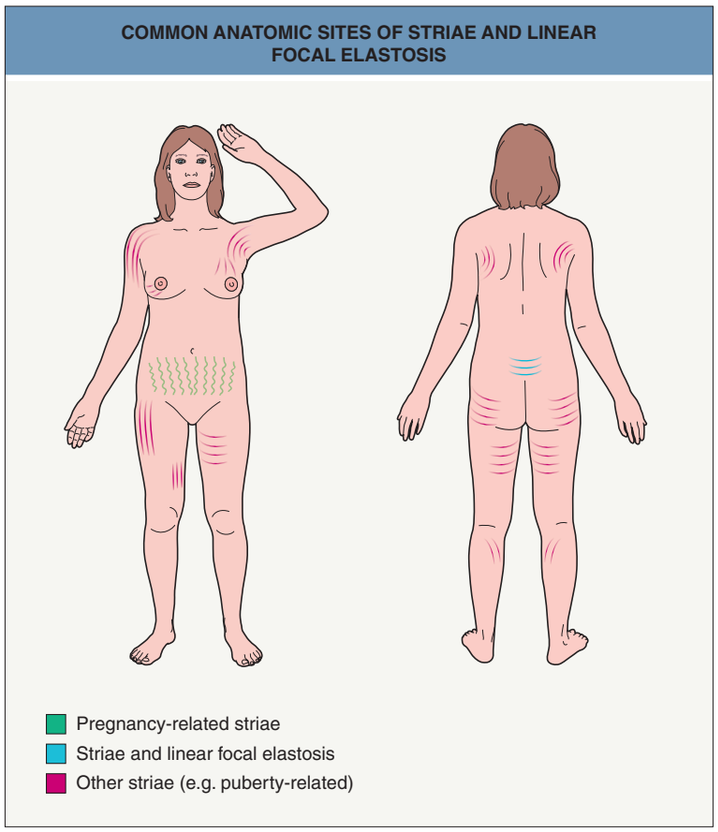

Fig. 99.6 Common anatomic sites of striae and linear focal elastosis. Striae associated with pregnancy are in green and lesions of linear focal elastosis are in blue.

Treatment

Striae distensae have no medical consequences, but they are frequently distressing to those afflicted. As striae tend to improve spontaneously over time, the value of anecdotal therapies without case controls is difficult to assess. Topical treatments that have shown some benefit in early-stage striae include tretinoin 0.1% cream[33] and a combination of 20% glycolic acid with either 0.05% tretinoin or 10% L-ascorbic acid[34]. The evidence for the effect of other topical treatments, either in prevention or treatment of striae, is inconclusive[34].

Several lasers have been used to treat striae: the 585 nm pulsed dye laser may improve the appearance of striae rubrae, but it has no effect on striae albae; secondary pigmentary alterations in darker skin are a potential complication[35]. Improvement of striae albae was noted with fractionated non-ablative lasers, presumably via neocollagenesis[36]. Use of radiofrequency and pulsed magnetic fields may also lead to improvement[37]. However, currently, there is no specific therapy that results in a complete response.

ATROPHODERMA OF PASINI AND PIERINI

Synonyms: ▪ Idiopathic atrophoderma of Pasini and Pierini ▪ Atrophoderma ▪ Sclérodermie atrophique d'emblée ▪ Morphea plana atrophica

Key features

- Depressed patches, usually on the posterior trunk and brown in color
- "Cliff-drop" or abrupt transition from normal to diseased skin
- Lesions are asymptomatic and lack induration
- Disorder lasts for many years but has a benign course

Introduction

Atrophoderma of Pasini and Pierini is a form of dermal atrophy that presents as one or more sharply demarcated depressed patches, usually on the back of adolescents or young adults. Whether atrophoderma represents an atypical, primarily atrophic form of morphea or "burnt-out" morphea or a separate distinct entity is still debated.

Downloaded for Anonymous User (n/a) at Egyptian Knowledge Bank from ClinicalKey.com by Elsevier on March 10, 2024. For personal use only. No other uses without permission. Copyright ©2024. Elsevier Inc. All rights reserved.

History

In 1923, Pasini described atrophic cutaneous lesions on the trunk of a 21-year-old woman that he referred to as progressive idiopathic atrophoderma[38]. In 1936, and over the subsequent years, Pierini and associates extensively studied and defined the condition and its possible link to morphea. This prompted Canizares et al.[39] in 1958 to rename this entity "idiopathic atrophoderma of Pasini and Pierini".

Epidemiology

This disorder is more frequently encountered in women than in men, with a ratio of 6:1 in adults[40]. It usually starts insidiously in young individuals during the second or third decade of life. However, a number of cases have been described in children younger than 13 years of age. More recently, rare congenital cases have been reported[41].

Pathogenesis

The etiology of atrophoderma of Pasini and Pierini remains as yet unknown. Some authors have suggested the possible role of *Borrelia burgdorferi* infection, as in acrodermatitis chronica atrophicans, since a positive serology can be found in up to 40%–50% of European patients[42]. However, false-positive results can occur, and results have varied widely. Given some overlap between atrophoderma and morphea, perhaps insights into the pathogenesis of the latter will provide clues to the former.

Clinical features

Lesions usually appear on the trunk, especially the back and lumbosacral region, followed in frequency by the chest, arms, and abdomen[42]. The face, hands, and feet are usually spared. The distribution is often symmetric and bilateral, but a linear pattern along the lines of Blaschko has been described (atrophoderma of Moulin; see Ch. 67).

The lesions are single or multiple and usually round or ovoid, ranging in size from a few centimeters to patches covering large areas of the trunk. They are usually asymptomatic and lack inflammation. When lesions coalesce, they can form large irregular patches. The patches usually have a brown color (Fig. 99.7), but some are blue to violet in color or occasionally hypopigmented[43]. The surface of the skin is normal in appearance, as is the consistency upon palpation. There is a lack of cutaneous induration or sclerosis.

The borders or edges of these lesions are sharply defined, and they are usually described as abrupt "cliff-drop" borders ranging from 1 to 8 mm in depth, although they can have a gradual slant and the depression may be subtle[39]. These depressed patches often give the impression of inverted plateaus, or, if multiple lesions are present, they can have the appearance of Swiss cheese. The lesions are even more apparent when present on the back, because the dermis is thicker in this area. Occasionally, dermal blood vessels are visible within the depressed patches.

The skin surrounding the patches is normal in appearance, and there is no erythema or lilac ring as in morphea. However, typical lesions of morphea, lichen sclerosus, and atrophoderma have been observed to occur simultaneously in the same patient (but in different areas), supporting the view that these conditions are related[44]. In addition, sclerodermatous changes can occasionally appear years later in the center of the depressed lesions, leading to a white, shiny induration[39]. In a series of 139 patients, 17% had a white induration in the central portions of their atrophic lesions, and, in 22%, superficial plaques of morphea coexisted in sites separate from the atrophic foci[40].

The course of this benign disease is progressive, and lesions can continue to appear for decades before reaching a standstill. Transformation to generalized morphea has not been observed.

Fig. 99.7 Atrophoderma of Pasini and Pierini. A, B Multiple light brown patches on the back; note the subtle depression of the lesions with a "cliff-drop" edge. In A, dermal blood vessels are easily seen within a few patches; the white papule is a healed biopsy site. *A, Courtesy Julie V. Schaffer, MD; B, Courtesy Catherine C. McCuaig, MD.*

Pathology

In general, the histologic picture is not diagnostic, so the diagnosis is primarily a clinical one. The epidermis is usually normal or slightly atrophic. Pigmentation of the basal layer may be increased. A perivascular infiltrate consisting of T cells and histiocytes may be seen. Collagen bundles in the reticular dermis show varying degrees of homogenization and clumping. Dermal thickness is reduced when compared with adjacent normal skin[45]. Dermal atrophy is difficult to evaluate on a punch biopsy, but it can be more easily demonstrated if an elliptical biopsy is taken in an area that includes the cliff-drop border and is then sectioned longitudinally to show the transition between normal and lesional skin.

In most series, no abnormality has been observed with elastic tissue stains[40,42]; however, a retrospective study described a spectrum of changes, ranging from normal to severe diminution and fragmentation of the elastic fiber network[43]. The adnexal structures are usually preserved. If sclerodermatous changes appear within pre-existing lesions, varying degrees of collagen sclerosis resembling morphea can be seen. Of note, evaluation of collagen and elastic fibers by multiphoton microscopy has suggested that the atrophic appearance of atrophoderma reflects changes in the organization of collagen and elastic fibers, not a variation in their content[46].

Direct immunofluorescence may show nonspecific IgM and C3 staining in the dermal papillary blood vessels in early lesions or at the dermal–epidermal junction[47].

Differential diagnosis

Since the original description, there has been much discussion over whether atrophoderma of Pasini and Pierini is a distinct entity or an atrophic, non-indurated, perhaps "burnt-out" variant of morphea (see Ch. 44). Active lesions of morphea present as indurated, often hyperpigmented plaques with a characteristic peripheral lilac rim.

Although atrophoderma of Pasini and Pierini lacks sclerosis[40,42,44,47], its relationship to morphea is favored by its striking clinical and

Downloaded for Anonymous User (n/a) at Egyptian Knowledge Bank from ClinicalKey.com by Elsevier on March 10, 2024. For personal use only. No other uses without permission. Copyright ©2024. Elsevier Inc. All rights reserved.

histologic similarities to the atrophy seen at sites of regressing plaques of morphea. To some, the different course and outcome of atrophoderma of Pierini and Pasini as compared with morphea justifies preservation of a distinct name.

Anetoderma, also an atrophic dermal process, is easily differentiated by palpation and histology, which consistently shows a loss of elastic fibers in the dermis (as opposed to a loss of collagen).

Treatment

The natural course of the disease is often protracted (10–20 years) but self-healing, making evaluation of therapy difficult. No treatment has been proven effective. In view of the possibility of underlying *Borrelia* infection, penicillin and doxycycline have been used to treat atrophoderma of Pasini and Pierini, but the results have been variable[42,48]. A dramatic response to oral hydroxychloroquine was reported in one patient[49], and Q-switched alexandrite laser may diminish the associated hyperpigmentation[50].

FOLLICULAR ATROPHODERMA

Follicular atrophoderma refers to dimple-like depressions at the follicular orifices. It can occur as an isolated defect of limited extent, in association with a variety of disorders in which hair follicles are plugged with keratin, or with rare genodermatoses.

In 1944, Miescher described follicular atrophoderma in an 8-year-old girl with atypical chondrodystrophy[51]. Six years later, Curth also used the term follicular atrophoderma (although there was no evidence of follicular atrophy but rather follicular agenesis) and further reported in 1978 on the genetics of follicular atrophoderma[52].

Clinical features

Distinctive follicular ice-pick depressions can be seen most commonly on the back of the hands and feet or on the cheeks. These pitted scars are often present at birth or appear during childhood. A family history may be present. Follicular atrophoderma can be associated with Bazex–Dupré–Christol and Conradi–Hünermann–Happle syndromes. When the lesions are found exclusively on the cheeks, the term "atrophoderma vermiculatum" applies. Atrophoderma vermiculatum can in turn be associated with various disorders discussed in the next section.

Atrophoderma Vermiculatum

Atrophoderma vermiculatum, a disorder limited to the face, has been described under a variety of names, including ulerythema acneiforme, acne vermoulante, atrophoderma reticulata symmetrica faciei, folliculitis ulerythema reticulata, folliculitis ulerythemosa, and honeycomb atrophy ("ulerythema" means scar plus redness and "vermiculatum" means worm-eaten).

Atrophoderma vermiculatum may: (1) occur sporadically; (2) be inherited as an autosomal dominant disorder; (3) be part of a group of related diseases that are referred to as "keratosis pilaris atrophicans" (see Table 38.2); or (4) be associated with various syndromes.

Multiple symmetric inflammatory papules on the cheeks, presumably centered around hair follicles, may precede the atrophic lesions. These papules then go on to become pitted, atrophic, depressed scars in a reticulated or honeycomb pattern (Fig. 99.8). The severity of erythema varies, as does the presence of milia and horny follicular plugs. Lesions can extend to the forehead and preauricular regions. Onset is usually in childhood or, less often, around puberty. Both sexes appear to be equally affected[53], and it usually has a slowly progressive course.

Atrophoderma vermiculatum can be associated with a group of closely related disorders referred to as keratosis pilaris atrophicans (see Table 38.2)[54]. This group also includes keratosis follicularis spinulosa decalvans and ulerythema ophryogenes. These conditions are characterized by keratotic follicular papules, variable degrees of inflammation, and secondary atrophic scarring. Ulerythema ophryogenes (or keratosis pilaris atrophicans faciei) differs from atrophoderma vermiculatum by affecting primarily the lateral portion of the eyebrows (ophryogenes) in the form of erythema, follicular papules, and alopecia. The inheritance pattern is autosomal dominant with incomplete penetrance and occasionally autosomal recessive, with progression usually ceasing after puberty. Keratosis follicularis spinulosa decalvans begins during

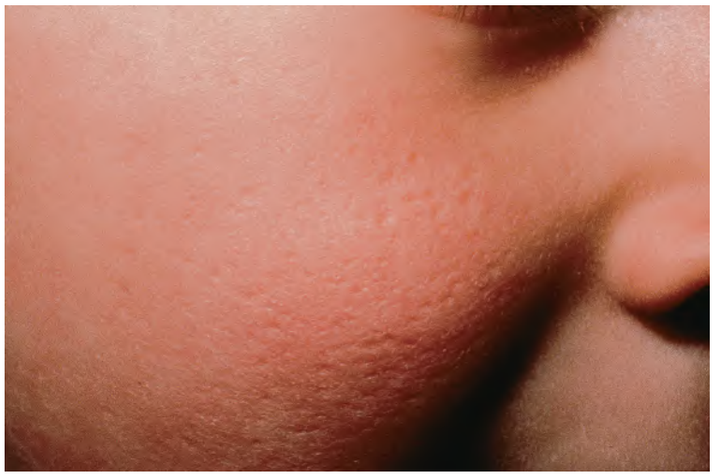

Fig. 99.8 Atrophoderma vermiculatum. Multiple small pitted scars on the cheek of a young girl. Note the honeycomb pattern on the lower inner cheek; the skin is said to appear "worm-eaten". *Courtesy Robert Hartman, MD.*

childhood as keratotic follicular papules on the malar area and progresses to involve the eyebrows, scalp, and extremities, with associated scarring alopecia. In most patients, this disorder is inherited in an X-linked recessive fashion.

The underlying pathogenesis in atrophoderma vermiculatum as well as the other disorders in the keratosis pilaris atrophicans group appears to be abnormal follicular hyperkeratinization. The latter occurs in the upper third of the hair follicle, leading to obstruction of the growing hair shaft and production of chronic inflammation. The end result is scarring below the level of obstruction.

Histopathology is usually not very helpful and shows dilated follicles, sometimes associated with plugging, inflammation, and sclerosis of dermal collagen.

Syndromes associated with atrophoderma vermiculatum include Rombo syndrome (milia, telangiectasias, basal cell carcinomas [BCCs], hypotrichosis, acrocyanosis, and, occasionally, trichoepitheliomas) and Loeys–Dietz syndrome (see Ch. 95), in addition to the less well characterized Nicolau–Balus syndrome (syringomas and milia), Tuzun syndrome, and Braun–Falco–Marghescu syndrome (congenital poikiloderma).

The differential diagnosis of atrophoderma vermiculatum includes atrophia maculosa varioliformis cutis, keratosis pilaris rubra of the cheeks, and, in older adults, erythromelanosis faciei.

This disorder is primarily a cosmetic problem. Various topical treatments, including emollients, corticosteroids, tretinoin and keratolytics, have shown no consistent benefit. In some instances, systemic isotretinoin has been shown to stop progression and to induce remission[54]. Dermabrasion, laser therapy (e.g. CO_2, 585 nm pulsed dye), and fillers (e.g. hyaluronic acid, autologous fat) are other options for improving the appearance of the atrophic scars[55].

Bazex–Dupré–Christol Syndrome

Bazex, Dupré and Christol first described this genodermatosis in 1964, not to be confused with Bazex syndrome (acrokeratosis paraneoplastica) in which hyperkeratotic plaques of the ears, nose, cheeks, hands, feet and knees are associated with carcinomas of the upper aerodigestive tract (see Ch. 53). Bazex–Dupré–Christol syndrome is characterized by follicular atrophoderma, milia, multiple BCCs, hypotrichosis, and localized hypohidrosis (above the neck)[56]. It is inherited in an X-linked dominant fashion, and the gene has been linked to Xq24–q27[57]. Additional reported findings include facial hyperpigmentation, hair shaft anomalies, and multiple trichoepitheliomas. Systemic manifestations are absent. Recently, it was suggested that this syndrome might better be classified as an ectodermal dysplasia[58].

The follicular atrophoderma, described as multiple ice-pick marks or patulous follicles, is found most commonly on the dorsal aspect of the hands, but can also be seen on the feet, lower back, elbows, and occasionally the face; it may be present at birth or appear later during childhood. No abnormalities of the elastic fibers have been found (nor any evidence of atrophy of the epidermis, hair or dermis), making the term "follicular atrophoderma" a misnomer. The histopathology usually

Downloaded for Anonymous User (n/a) at Egyptian Knowledge Bank from ClinicalKey.com by Elsevier on March 10, 2024. For personal use only. No other uses without permission. Copyright ©2024. Elsevier Inc. All rights reserved.

shows hair follicles that are abnormally wide, plugged, and surrounded by an inflammatory cell infiltrate and clusters of basaloid cells. Sweat glands can be absent.

BCCs develop in about 40% of patients (primarily on the face) and can resemble melanocytic nevi; the age of onset varies from 9 to 50 years of age. To date, ~20 families with this syndrome have been described.

The differential diagnosis includes other genodermatoses with multiple BCCs: basal cell nevus syndrome (Gorlin syndrome), an autosomal dominant disorder most commonly due to mutations in *PTCH1* (see Ch. 108); Rombo syndrome, an autosomal dominant disorder characterized by BCCs, atrophoderma vermiculatum, milia, hypotrichosis, acrocyanosis, and, occasionally, trichoepitheliomas; and xeroderma pigmentosum (see Ch. 86).

Conradi–Hünermann–Happle Syndrome (X-Linked Dominant Chondrodysplasia Punctata, CDPX2)

Conradi–Hünermann–Happle syndrome is an X-linked dominant disorder that occurs almost exclusively in girls, since it is usually lethal in hemizygous males. This form of chondrodysplasia punctata results from mosaicism for mutations in the gene on the X chromosome that encodes the emopamil-binding protein[59,60]. The clinical manifestations include ichthyosiform streaks (composed of erythema plus feathery, adherent scale) patterned along the lines of Blaschko; they usually resolve during the first year of life and are replaced by bands of follicular atrophoderma[60]. Hyperpigmentation, cataracts, scarring alopecia, saddle-nose deformity, asymmetric limb reduction defects, and stippled calcifications of the epiphyses are additional manifestations (see Ch. 57). Within the ichthyosiform areas in newborns, keratotic follicular plugs containing dystrophic calcification is a distinctive histopathologic feature[59].

ATROPHIA MACULOSA VARIOLIFORMIS CUTIS

Atrophia maculosa varioliformis cutis was first described by Heidingsfeld in 1918[61] and is not as rare as the number of published cases would suggest. It consists of small round "varioliform" and linear facial depressions that are asymptomatic (Fig. 99.9)[62]. It occurs spontaneously on the cheeks and occasionally involves the forehead or chin. There is a gradual increase in the number of lesions, but in the absence of preceding trauma, acne, or inflammatory lesions. A familial variant has been described. Pachydermodactyly and extrahepatic biliary atresia have been associated findings, but this association is probably fortuitous. The pathogenesis is unknown.

The histologic changes include a depression of the epidermis and normal collagen fibers, but a slightly decreased number of elastic fibers. There is usually little or no inflammation. The differential diagnosis includes simple scars, which can be differentiated by history and the presence histologically of dermal fibrosis, and atrophoderma vermiculatum. The latter is harder to differentiate, but it can present with inflammatory papules that are followed by pitted scars, and atrophoderma vermiculatum usually has a honeycombed (rather than sharply linear) pattern and is usually centered on hair follicles. There is no known treatment to prevent the occurrence of these lesions.

PIEZOGENIC PEDAL PAPULES (PIEZOGENIC PAPULES)

Piezogenic pedal papules were first described by Shelley and Rawnsley in 1968[63]. This term is somewhat of a misnomer as piezogenic means "producing pressure", when in fact these lesions are produced by pressure. It is postulated that pressure induces herniation of fat through connective tissue in the dermis of the heels.

These papules are common enough in the general population to be considered normal and have also been described in association with Ehlers–Danlos syndrome, Prader–Willi syndrome, and GATA2 deficiency[64]. An infantile variant characterized by larger nodules on the medial aspect of the heel (present without weight-bearing) has been described[65] and is referred to as pedal papules of infancy and more recently, precalcaneal congenital fibrolipomatous hamartoma (Fig. 99.10). When unilateral, this entity has to be distinguished from juvenile aponeurotic fibroma which can calcify.

Skin-colored papules and nodules are seen on the sides of the heels (Fig. 99.11); they are induced by weight-bearing and disappear when the leg is

Fig. 99.10 Pedal papules of infancy (precalcaneal congenital fibrolipomatous hamartoma). Soft nodules on the medial and plantar surfaces of the foot. *Courtesy Julie V. Schaffer, MD.*

Fig. 99.9 Atrophia maculosa varioliformis cutis. Multiple linear scar-like depressions (between and above arrows) with no history of trauma. *Courtesy Jean L. Bolognia, MD.*

Fig. 99.11 Piezogenic pedal papules. Soft papulonodules on the heel. *Courtesy Benoit Côté, MD.*

Downloaded for Anonymous User (n/a) at Egyptian Knowledge Bank from ClinicalKey.com by Elsevier on March 10, 2024. For personal use only. No other uses without permission. Copyright ©2024. Elsevier Inc. All rights reserved.

raised. The lesions are usually asymptomatic, but pain has been described during weight-bearing, and, in these cases, an orthopedic shoe or surgical excision may help. Similar lesions have been described on the wrists[66].

OTHER ATROPHIES OF THE CONNECTIVE TISSUE

Many systemic conditions (lupus erythematosus, dermatomyositis) and genodermatoses (Rothmund–Thomson syndrome, dyskeratosis congenita, Cockayne syndrome, Hallermann–Streiff syndrome) have cutaneous atrophy (epidermal, dermal, and/or subcutaneous) as an associated finding. Lichen sclerosus is discussed in Chapter 44, progeria in Chapter 63, Ehlers–Danlos syndrome and cutis laxa in Chapter 97, and acrodermatosis chronica atrophicans in Chapter 74. Cutaneous atrophy is also a well-known complication of prolonged use of either systemic or topical corticosteroids (see Ch. 125).

Additional figures available in our eBook (see inside front cover for access code).

REFERENCES

1. Shelley WB, Wood MG. Wrinkles due to idiopathic loss of mid-dermal elastic tissue. *Br J Dermatol*. 1977;97:441–445.
2. Hardin J, Dupuis E, Haber RM. Mid-dermal elastolysis: a female-centric disease; case report and updated review of the literature. *Int J Womens Dermatol*. 2015;1:126–130.
3. Gambichler T, Mamali K, Scheel C. A brief literature update on mid-dermal elastolysis with an emphasis on pathogenetic and therapeutic aspects. *J Clin Aesthet Dermatol*. 2020;13:e53–e58.
4. Snider RL, Lang PG, Maize JC. The clinical spectrum of mid-dermal elastolysis and the role of UV light in its pathogenesis. *J Am Acad Dermatol*. 1993;28:938–942.
5. Vatve M, Morton R, Bilsland D. A case of mid-dermal elastolysis after narrowband ultraviolet B phototherapy. *Clin Exp Dermatol*. 2009;34:263–264.
6. Gambichler T, Breuckmann F, Kreuter A, et al. Immunohistochemical investigation of mid-dermal elastolysis. *Clin Exp Dermatol*. 2004;29:192–195.
7. Gambichler T, Skrygan M. Decreased lysyl oxidase-like 2 expression in mid-dermal elastolysis. *Arch Dermatol Res*. 2013;305:359–363.
8. Gambichler T, Reininghaus L, Skrygan M, et al. Fibulin protein expression in mid-dermal elastolysis and anetoderma: a study of 23 cases. *Acta Derm Venereol*. 2016;96:708–710.
9. Scola N, Goulioumis A, Gambichler T. Non-invasive imaging of mid-dermal elastolysis. *Clin Exp Dermatol*. 2011;36:155–160.
10. Smithson SL, Orchard D, Scardamaglia L. Mycophenolate mofetil to treat mid-dermal elastolysis. *Pediatr Dermatol*. 2018;35:e221–e223.
11. Jadassohn J. Uber eine eigenartige form von 'atrophica maculosa cutis'. *Arch Dermatol Syphilol*. 1892;24:342–358.
12. Schweninger E, Buzzi F. *Multiple benign tumor-like new growths of the skin*. *International Atlas Sellltener Hautkrankheiten, plate 15*. Leipzig: L Voss;; 1891.
13. Venencie PY, Bonnefoy A, Gogly B, et al. Increased expression of gelatinases A and B by skin explants from patients with anetoderma. *Br J Dermatol*. 1997;137:517–525.
14. Brys AK, Rodriguez-Homs LG, Wennerberg S, et al. Anetoderma associated with a succinate dehydrogenase gene mutation: a potental link between anetoderma and citric acid cycle mutations. *JAMA Dermatol*. 2019;155:1317–1318.
15. Venencie PY, Winkelmann RK, Moore BA. Anetoderma: clinical findings, associations, and long-term follow-up evaluations. *Arch Dermatol*. 1984;120:1032–1039.
16. Patrizi A, Neri I, Virdi A, et al. Familial anetoderma: a report of two families. *Eur J Dermatol*. 2011;21:680–685.
17. Hodak E, David M. Primary anetoderma and antiphospholipid antibodies – review of the literature. *Clin Rev Allergy Immunol*. 2007;32:162–166.
18. Gougeon E, Beer F, Gay S, et al. Anetoderma of prematurity: an iatrogenic consequence of neonatal intensive care. *Arch Dermatol*. 2010;146:565–567.
19. Venecie PY, Wilkelmann RK. Histopathologic findings in anetoderma. *Arch Dermatol*. 1984;120:1040–1044.
20. Bergman R, Friedman-Birnbaum R, Hazaz B, et al. An immunofluorescence study of primary anetoderma. *Clin Exp Dermatol*. 1990;15:124–130.
21. Sezer E, Durmaz EO, Sahin S. Papular elastorrhexis: clinical perspectives. *Clin Cosmet Investig Dermatol*. 2018;11:541–544.
22. Cho S, Jung JY, Lee JH. Treatment of anetoderma occurring after resolution of Stevens-Johnson syndrome using an ablative 10,600-nm carbon dioxide fractionated laser. *Dermatol Surg*. 2012;38:677–679.
23. Wang K, Ross NA, Saedi N. Anetoderma treated with combined 595-nm pulsed-dye laser and 1550-nm non ablative fractionated laser. *J Cosmet Laser Ther*. 2016;18:38–40.
24. Hirt PA, Castillo DE, Yosipovitch G, Keri JE. Skin changes in the obese patient. *J Am Acad Dermatol*. 2019;81:1037–1057.
25. Elsedfy H. Striae distensae in adolescents: a mini review. *Acta Biomed*. 2020;91:176–181.
26. Farahnik B, Park K, Kroumpouzos G, Murase J. Striae gravidarum: risk factors, prevention and management. *Int J Womens Dermatol*. 2017;3:77–85.
27. Farber SA, Samimi S, Rosenbach M. Ulcerations within striae distensae associated with bevacizumab therapy. *J Am Acad Dermatol*. 2015;72:e33–e35.
28. Wahman AJ, Finan MA, Emerson SC. Striae gravidarum as a predictor of vaginal lacerations at delivery. *South Med J*. 2000;93:873–876.
29. Salter SA, Batra RS, Rohrer TE, et al. Striae and pelvic relaxation: two disorders of connective tissue with a strong association. *J Invest Dermatol*. 2006;126:1745–1748.
30. Al-Himdani SI, Ud-Din S, Gilmore S, Bayat A. Striae distensae: a comprehensive review and evidence-based evaluation of prophylaxis and treatment. *Br J Dermatol*. 2014;170:527–547.
31. Burket JM, Zelickson AS, Padilla RS. Linear focal elastosis (elastotic striae). *J Am Acad Dermatol*. 1989;20:633–636.
32. Hashimoto K. Linear focal elastosis: keloidal repair of striae distensae. *J Am Acad Dermatol*. 1998;39:309–313.
33. Kang S. Topical tretinoin therapy for management of early striae. *J Am Acad Dermatol*. 1998;39:S90–S92.
34. Ud-Din S, McGeorge D, Bayat A. Topical management of striae distensae (stretch marks): prevention and therapy of straie rubrae and albae. *J Eur Acad Dermatol Venereol*. 2016;30:211–222.
35. Forbat E, Al-Niaimi F. Treatment of striae distensae: an evidence-based approach. *J Cosmet Laser Ther*. 2019;21:49–57.
36. Aldahan AS, Shah VV, Mlacker S, et al. Laser and light treatments for striae distensae: a comprehensive review of the literature. *Am J Clin Dermatol*. 2016;17:239–256.
37. Ramault L, Hoeksema H, Pirayesh A, et al. Microneedling: where do we stand now? A systematic review of the literature. *J Plast Reconstr Aesthet Surg*. 2018;71:1–14.
38. Pasini A. Atrophoderma idiopathica progressiva. *Gior Ital Derm Sif*. 1923;58:785.
39. Canizares O, Sachs PM, Jaimovich L, Torres VM. Idiopathic atrophoderma of Pasini and Pierini. *Arch Dermatol*. 1958;77:42–60.
40. Muntyanu A, Redpath M, Roshdy O, Jfri A. Idiopathic atrophoderma of Pasini and Pierini: case report and literature review. *Clin Case Rep*. 2019;7:258–263.
41. Kang CY. Lam. J. Congenital idiopathic atrophoderma of Pierini and Pasini. *Int J Dermatol*. 2015;54:e44–e46.
42. Buechner SA, Rufli T. Atrophoderma of Pasini and Pierini: clinical and histopathologic findings and antibodies to *Borrelia burgdorferi* in thirty-four patients. *J Am Acad Dermatol*. 1994;30:441–446.
43. Saleh Z, Abbas O, Dahdah MJ, et al. Atrophoderma of Pierini and Pasini: a clinical and histopathological study. *J Cutan Pathol*. 2008;35:1108–1114.
44. Amano H, Nagai Y, Ishikawa O. Multiple morphea coexistent with atrophoderma of Pierini-Pasini (APP): APP could be abortive morphea. *J Eur Acad Dermatol Venereol*. 2007;21:1254–1256.
45. Yokoyama Y, Akimoto S, Ishikawa O. Disaccharide analysis of skin glycosaminoglycans in atrophoderma of Pasini and Pierini. *Clin Exp Dermatol*. 2000;25:436–440.
46. Viera-Damiani G, Lage D, Christofoletti Daldon PE, et al. Idiopathic atrophoderma of Pasini and Pierini: a case study of collagen and elastin texture by multiphoton microscopy. *J Am Acad Dermatol*. 2017;77:930–937.
47. Berman A, Berman GD, Kinnkelmann RK. Atrophoderma (Pasini-Pierini): findings on direct immunofluorescent, monoclonal antibody, and ultrastructural studies. *Int J Dermatol*. 1988;27:487–490.
48. Lee Y, Oh Y, Ahn SY, et al. A case of atrophoderma of Pasini and Pierini associated with *Borrelia burgdorferi* infection successfully treated with oral doxycycline. *Ann Dermatol*. 2011;23:352–356.
49. Carter JD, Valeriano J, Vasey FB. Hydroxychloroquine as a treatment for atrophoderma of Pasini and Pierini. *Int J Dermatol*. 2006;45:1255–1256.
50. Arpey CJ, Patel DS, Stone MS, et al. Treatment of atrophoderma of Pasini and Pierini-associated hyperpigmentation with Q-switched alexandrite laser: a clinical, histologic, and ultrastructural appraisal. *Lasers Surg Med*. 2000;27:206–212.
51. Miescher G. Atypische Chondrodystrophie, Typus morquino kombiniert mit follikularer atrophodermie. *Dermatologica*. 1944;89:38–51.
52. Curth HO. The genetics of follicular atrophoderma. *Arch Dermatol*. 1978;114:1479–1483.
53. Luria RB, Conologue T. Atrophoderma vermiculatum: a case report and review of the literature on keratosis pilaris atrophicans. *Cutis*. 2009;83:83–86.
54. Callaway SR, Lesher JL. Keratosis pilaris atrophicans: case series and review. *Pediatr Dermatol*. 2004;21:14–17.
55. Handrick C, Alster T. Laser treatment of atrophoderma vermiculata. *J Am Acad Dermatol*. 2001;44:693–695.
56. AlSabbagh MM, Baqi MA. Bazex-Dupré-Christol syndrome: review of clinical and molecular aspects. *Int J Dermatol*. 2018;57:1102–1106.
57. Parren LJ, Abuzahra F, Wagenvoort T, et al. Linkage refinement of Bazex-Dupré-Christol syndrome to an 11-4-Mb interval on chromosome Xq25-27.1. *Br J Dermatol*. 2011;165:201–203.
58. Castori M, Castiglia D, Passarelli F, et al. Bazex-Dupré-Christol syndrome: an ectodermal dysplasia with skin appendage neoplasms. *Eur J Med Genet*. 2009;52:250–255.
59. Hoang MP, Carder KR, Pandya AG, Bennettt MJ. Ichthyosis and keratotic follicular plugs containing dystrophic calcification in newborns: distinctive histopathologic features of X-linked dominant chondrodysplasia punctata (Conradi-Hünermann-Happle syndrome). *Am J Dermatopathol*. 2004;26:53–58.
60. Canueto J, Giros M, Ciria S, et al. Clinical, molecular and biochemical characterization of nine Spanish families with Conradi-Hünermann-Happle syndrome: new insights into X-linked dominant chondrodysplasia punctata with a comprehensive review of the literature. *Br J Dermatol*. 2012;166:830–838.
61. Heidingsfeld ML. Atrophia maculosa varioliformis cutis. *J Cutan Dis*. 1918;36:285–288.
62. Kuflik JH, Schwartz RA, Becker KA, Lambert WC. Atrophia maculosa varioliformis cutis. *Int J Dermatol*. 2005;44:864–866.
63. Shelley WB, Rawnsley JM. Painful feet due to herniation of fat. *JAMA*. 1968;205:308–309.
64. Amarnani AA, Poladian KR, Marciano BE, et al. A panoply of rheumatological manifestations in patients with GATA2 deficiency. *Sci Rep*. 2020;10:8305.
65. Greenberg S, Krafchik BR. Infantile pedal papules. *J Am Acad Dermatol*. 2005;53:333–334.
66. Laing VB, Fleischer Jr. AB. Piezogenic wrist papules: a common and symptomatic finding. *J Am Acad Dermatol*. 1991;24:415–417.

Downloaded for Anonymous User (n/a) at Egyptian Knowledge Bank from ClinicalKey.com by Elsevier on March 10, 2024. For personal use only. No other uses without permission. Copyright ©2024. Elsevier Inc. All rights reserved.

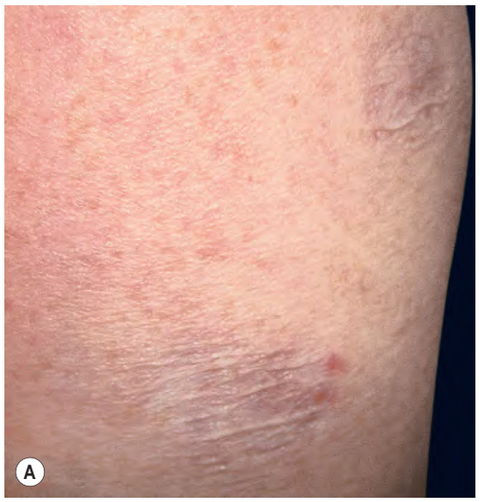

eFig. 99.1 Secondary anetoderma. Wrinkling of the skin at sites of sarcoidosis (**A**) and lepromatous leprosy (**B**). *B, Courtesy Louis A. Fragola, Jr, MD.*

eFig. 99.2 Linear focal elastosis. This is the most common site of involvement. Note that the lesions are elevated and yellowish in color.

eFig. 99.3 Atrophoderma of Pasini and Pierini. Coalescent hyperpigmented patches on the abdomen.

eFig. 99.4 Piezogenic pedal papules (piezogenic papules). Soft papules, primarily on the medial heel.

eFig. 99.5 Pedal papules of infancy (precalcaneal congenital fibrolipomatous hamartoma). Asymptomatic, symmetric soft nodules on the medial aspect of the heels persist in this 2-year-old child. *Courtesy Julie V. Schaffer, MD.*

Downloaded for Anonymous User (n/a) at Egyptian Knowledge Bank from ClinicalKey.com by Elsevier on March 10, 2024. For personal use only. No other uses without permission. Copyright ©2024. Elsevier Inc. All rights reserved.

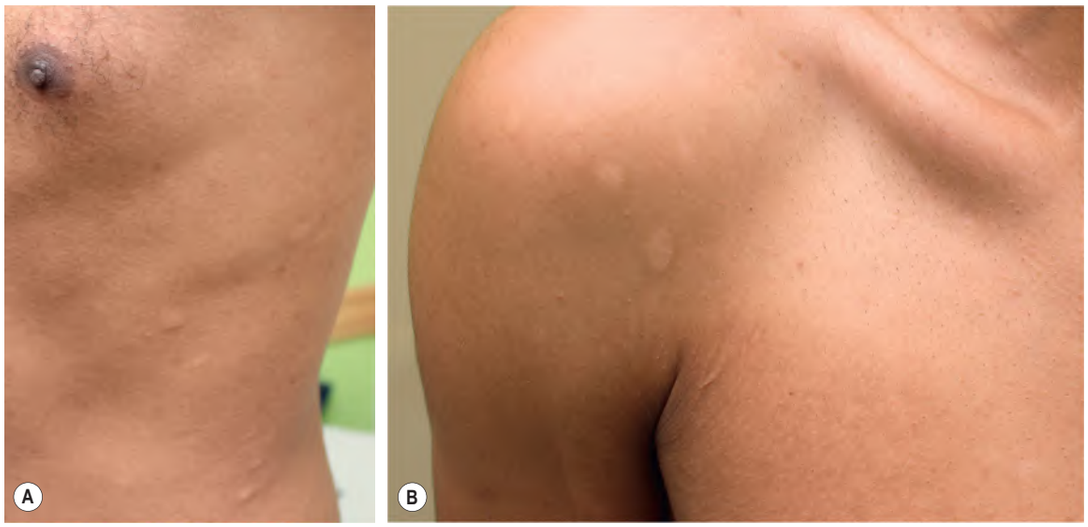

eFig. 99.6 Primary anetoderma. Lesions vary, from flat to soft papules that herniate upon palpation, and can appear hypopigmented. *Courtesy Kalman Watsky, MD.*

Downloaded for Anonymous User (n/a) at Egyptian Knowledge Bank from ClinicalKey.com by Elsevier on March 10, 2024. For personal use only. No other uses without permission. Copyright ©2024. Elsevier Inc. All rights reserved.